



Failure of Per-Oral Endoscopic Myotomy (POEM) for Achalasia Cardia—LES-Directed Therapy or Esophageal Body Therapy-Directed Therapy?: A Pictorial High-Resolution Esophageal Manometry (HREM) Case-Based Analysis

Zubin Dev Sharma¹ Rajesh Puri¹

¹ Department of Gastroenterology, Institute of Digestive & Hepatobiliary Sciences, Medanta Medicity, Gurugram, Haryana, India

J Digest Endosc

Address for correspondence Zubin Dev Sharma, MD, DNB, Department of Gastroenterology, Institute of Digestive & Hepatobiliary Sciences, Medanta Medicity, Gurugram 122001, Haryana, India (e-mail: drzubinsharma@gmail.com).

Abstract

Keywords

- achalasia cardia
- HREM
- POEM
- redo POEM

Per-oral endoscopic myotomy (POEM) is one of the main modalities of treatment of achalasia cardia today across subtypes and we are increasingly seeing patients persistent or recurrent symptoms after POEM. An accurate high-resolution esophageal manometry (HREM) is one of the most important tests that can help us guide the treatment in cases of failure of POEM. HREM can help us direct the therapy. The therapy can be lower esophageal sphincter-directed therapy or esophageal body-directed therapy that can be ascertained using HREM. With this review, we detail the factors associated with failure of POEM, tests that can be utilized for its evaluation, and case-based analysis using HREM in patients of post-POEM failure.

Introduction

Per-oral endoscopic myotomy (POEM) has become the mainstay for the management of patients of all subtypes of achalasia cardia in the last decade since its first description in humans by Inoue et al.¹ It has been widely used across the world and has been considered a game changer in third space endoscopic procedures. POEM has good clinical success and long-term results have also been now published.² Still around 1 to 2 patients out of 10 may not achieve successful outcomes. POEM has been shown to achieve superior results or at least equal results as laparoscopic Heller myotomy (LHM).³ With increasing numbers being done, there are lot of patients who come back with recurrent symptoms and possible POEM failures. A detailed analysis and accurate evaluation are required in these patients on understanding what went wrong and planning of rescue or remedial measures. In this review, we intend to

discuss various cases of POEM failure and how high-resolution esophageal manometry (HREM) can help us in identifying the underlying factor resulting in failure of POEM

Assessment of Failure of POEM-Defining Failure

The estimated clinical success of POEM is more than 95% at short term(<3 years) and more than 90% at 4 years of follow up. In major studies on factors associated with failure of POEM,^{4,5} an Eckardt score more than 3 after POEM is usually used in definition of post-POEM clinical failure. This should be lasting for at least 3 months time interval at any point post-POEM. In the study by Modayil et al,⁵ clinical failures at 30 months happened in only 4.8% of patients. Majority of patients in this subgroup had advanced disease, including sigmoid type esophagus or had prior treatment failures.

DOI <https://doi.org/10.1055/s-0044-1779339>.
ISSN 0976-5042.

© 2024. The Author(s).

This is an open access article published by Thieme under the terms of the Creative Commons Attribution License, permitting unrestricted use, distribution, and reproduction so long as the original work is properly cited. (<https://creativecommons.org/licenses/by/4.0/>)
Thieme Medical and Scientific Publishers Pvt. Ltd., A-12, 2nd Floor, Sector 2, Noida-201301 UP, India

Table 1 Factors associated with POEM failure

Preprocedural	<ul style="list-style-type: none"> • Pretreatment Eckardt score • Previous treatment for achalasia cardia • Sigmoid esophagus • Significant dilation of esophagus • Type 1 achalasia cardia • Long duration of symptoms
Intraprocedural	<ul style="list-style-type: none"> • Mucosal injury • Length of myotomy on gastric side • Empirical myotomy or HREM directed • Myotomy • Experience of the operator
Postprocedural	<ul style="list-style-type: none"> • LES pressures—Less than 40% decrease from baseline • Persistent raised IRP • Remnant muscle post-myotomy • GERD post-POEM

Abbreviations: GERD, gastroesophageal reflux disease; HREM, high-resolution esophageal manometry; IRP, integrated relaxation pressure; LES, lower esophageal sphincter; POEM, per-oral endoscopic myotomy.

In a large multicentric data published by Vauquelin et al,⁶ early failure was defined as Eckardt score of more than 3 at 3 months after POEM.

► **Table 1** shows the factors associated with failure of POEM.

Looking at the above studies, we can possibly divide POEM failures as very early (<3 months), early (3 months to 3 years), and late (>3 years). ► **Fig. 1** shows the use of HREM to plan the therapy for LES-directed or esophageal body-directed therapy based on findings. Very early failures post-POEM are possibly related more to technical factors, with early and late being more related to the patient-related or disease-related factors like prior treatments, sigmoid esophagus, or end-stage achalasia disease. It is also to be noted that patients can also present with similar symptoms of Eckardt score, which may be due to other illness and may falsely give impression of failure of POEM. Hence, it becomes imperative

that every case is individually analyzed and characterized with available techniques particularly HREM in identifying factors of failure.

Methods to Assess POEM Failure—Timed Barium Esophagogram (TBE) or HREM?

American College of Gastroenterology (ACG) guidelines recommend use of TBE as the first-line test to evaluate continued or recurrent symptoms after achalasia therapy. But most of this is based on older data. TBE has been utilized as the test to assess treatment of achalasia from the days of pneumatic dilation and LHM. In this patient ingests 250 ml of low-density barium and upright films at 1, 2, and 5 minutes are taken. The column of the retained barium is noted in height and width and this may be compared with pretreatment results. There have been few studies that have looked into use of TBE in assessing post-treatment outcomes.⁷ The above study had an interesting observation that despite that only 29% of patients had complete esophageal emptying at 1 minute, 36% at 2 minutes, and 49% at 5 minutes, 95% patients experienced complete or near complete relief. Majority of patients in this study group had undergone LHM. This tells us that even though TBE may show retention of barium, it may not correlate with symptoms of the patients. There is no association between improvement in TBE and symptom resolution.

There was a similar paper in which similar findings were reported after pneumatic balloon dilation of the LES from the same group.

In another paper by DeWitt et al⁸ in 2021, which evaluated the use of TBE after POEM, it was reported that contrast emptying rate by esophagogram after POEM has limited utility to predict clinical response or risk of postprocedure gastroesophageal reflux disease.

Sternbach et al⁹ also showed that early esophagogram (within 24 hours) also did not predict successful surgical outcomes.

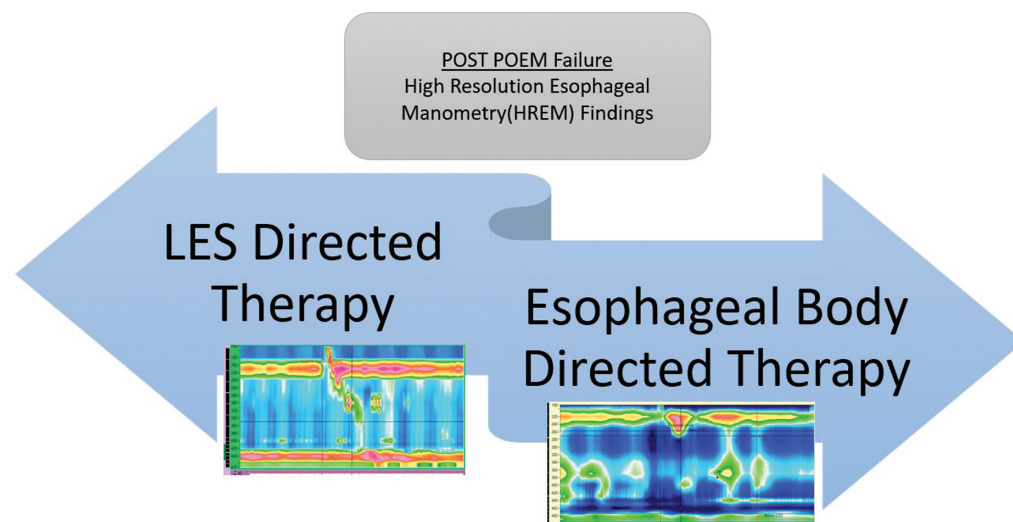


Fig. 1 Algorithm based on high-resolution esophageal manometry (HREM) findings in patients with per-oral endoscopic myotomy (POEM) failure. LES, lower esophageal sphincter.

Despite the above limitations, most of the published literature postintervention is available for TBE; hence, it still remains the investigation of choice in various expert comments and guidelines.

There has been increasing use of HREM in evaluation of persistent symptoms post-POEM in last decade with advent in HREM catheters that now go up to 36 channels. There is also development of high-definition catheters with more sensors and use of impedance-manometry catheters that combine impedance studies along with manometric pressures graphs. This developing technology has given us new tools to accurately assess the patients. HREM has also been shown to be a good indicator of therapeutic effectiveness. In an older study by Alonso et al,¹⁰ a resting sphincter pressures decrease to less than 12 mm Hg, and fall in pressures by more 40% of pretreatment levels correlated with successful outcomes.

Various metrics that have shown to be important on HREM include baseline LES pressures, pretreatment integrated relaxation pressure (IRP), post-treatment IRP, and lower esophageal sphincter (LES) pressures postinterventions. Other parameters include intraboli pressures postintervention. It is possible that these metrics can provide useful information about the degree of LES-induced resistance to flow in the post-POEM setting and guide therapy

HREM variables particularly IRP and resting LES pressures have been variably associated with successful outcomes; hence, ACG has in their recommendations mentioned that data are currently inadequate for use of HREM in assessing treatment failure for achalasia therapy.

With the use of subsequent case studies, we will like to highlight various factors that can be characterized on HREM and can lead to understanding of potential failures

With HREM, one can define clearly that LES-directed therapy is needed or esophageal body-directed therapy is needed based on parameters as seen in a case of post-POEM recurrent symptoms or dysphagia (→Fig. 2)

EndoFLIP or esophageal planimetry is another tool that has been found to be extremely useful in the assessment of post-POEM symptoms. It is increasingly being used in the west during and after POEM. One important thing to remember is that EndoFLIP looks in to secondary peristalsis or response of esophagus to distention, whereas HREM looks into primary peristalsis or response of esophagus to swallows. Hence, HREM is more physiological assessment of symptoms of the patient as compared with EndoFLIP, although studies have shown them to be equivalent. As it is not currently available in developing countries due to cost involved, we will limit our cases to utilization of HREM in assessment of symptoms after POEM.

Case 1: The Case of Incomplete Myotomy

A 45-year-old male was diagnosed to have type 3 achalasia cardia, based on HREM and endoscopy. His pre-POEM Eckardt score was 7. He was planned for long myotomy based on HREM. He underwent an uneventful POEM with good immediate relief. Two months after POEM, patient again had symptoms of dysphagia and chest pain. His Eckardt score again was 4. He underwent endoscopy and gastrografin swallow that were reported as normal. There was no resistance at gastro-esophageal junction. Patient was then referred for HREM for the evaluation of symptoms. →Fig. 2 shows post-POEM HREM image. →Fig. 3 also shows barium swallow of the patient that shows narrowing at the level of left out muscle.

In this case, we can clearly see the use of HREM to delineate the physiology. Patient has normal LES pressures with absence of pressurization in distal esophagus consistent with myotomy area during POEM. There is a pressurization zone just below the transition area between the skeletal and the smooth muscle part. This may reflect the remnant muscle in the proximal esophagus consistent with incomplete myotomy. To confirm these findings, patient has given oral sildenafil 25 mg and HREM repeated after 1 hour. As seen

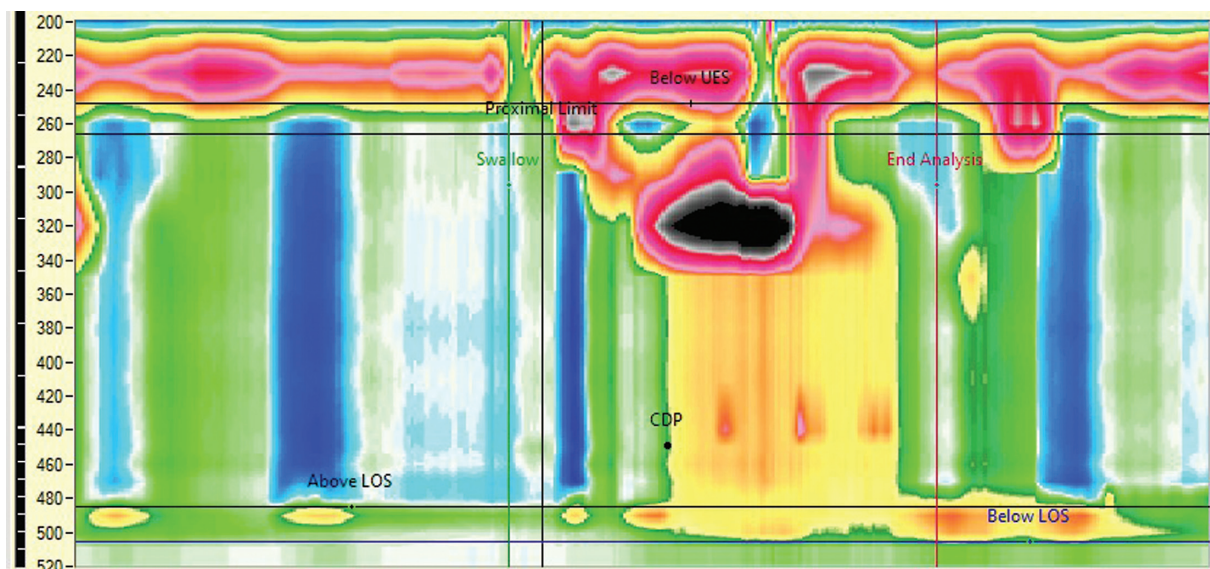


Fig. 2 High-resolution esophageal manometry showing incomplete myotomy in proximal esophagus in a patient with type 3 achalasia post-peroral endoscopic myotomy.

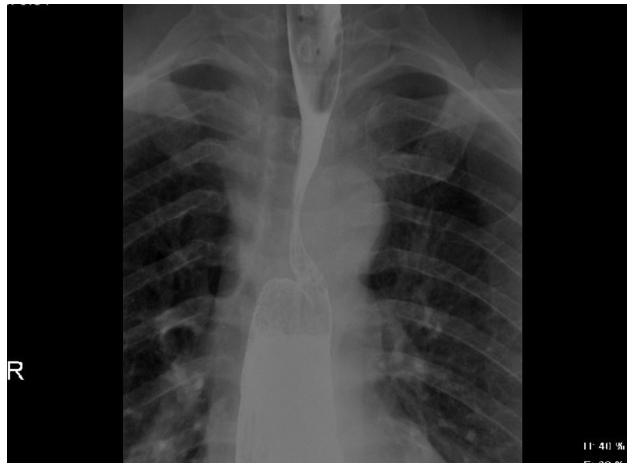


Fig. 3 Remnant_myotomy. Narrowing at level of remnant muscle after POEM.

in ►Fig. 4, there is a relaxation of the pressurization area and patient also reported relief in symptoms. The above findings confirmed the use of HREM in identifying remnant muscles or incomplete myotomy post-POEM in esophageal body. This patient was managed by use of PDE5 inhibitors for 1 year followed by redo POEM with limited myotomy of area involved based on HREM findings.

Case 2: The Case of Remnant LES Pressure

A 56-year-old male, who was diagnosed to have type 2 achalasia cardia, preintervention Eckardt score of 6, underwent posterior POEM with good short-term relief. After 12 months, patient again complained of dysphagia and reflux of symptoms. There was no TBE or HREM available post-POEM. Patient underwent upper gastrointestinal endoscopy (UGIE) that was reported as normal with no resistance at LES.

Patient underwent HREM using water perfused 24 channel catheter as shown in ►Fig. 5.

The wet swallow shows raised integrated relaxation pressure (IRP) at LES suggestive of incomplete relaxation

of LES. The distal esophagus shows absent peristalsis corresponding to previous myotomy. HREM here clearly defines that *patient needs LES directed therapy* in the form of redo POEM for relief of the symptoms. ►Fig. 6 shows retained barium swallow at 5 minutes and incomplete emptying of esophagus. This patient was managed with redo POEM with limited myotomy of LES on anterior side.

Case 3: The Case of Dilated Esophagus

A 67-year-old female presented with complaints of dysphagia, reflux symptoms, and nasal regurgitation for the last 10 years. She was diagnosed to be a case of achalasia cardia 7 years ago based on endoscopy and barium studies. Barium study showed a dilated esophagus and hold up of contrast at the level of LES. She did not undergo any HREM previously. She had undergone pneumatic dilation once 5 years ago with partial relief. Three years ago, she had undergone posterior POEM with short myotomy. She had significant relief in symptoms. Her pre-POEM Eckardt score was 6, and 2 months post-POEM Eckardt score was 2. In the last 1 year, she complained of persistent reflux symptoms that happened everyday and also associated dysphagia. She underwent HREM as shown in ►Fig. 7

►Fig. 7 shows complete absence of contractility in the esophageal body and normal pressures at the level of LES and normal IRP.

This HREM image suggests that patient's symptoms are not caused by LES dysfunction as there is no raised IRP. The symptoms are suggestive of progressive dysfunction of the esophageal body due to achalasia cardia. This patient will need *esophageal body-directed therapy*, possibly in the form of esophagectomy if symptoms are persistent.

Case 4: The Case of Blow-Out Myotomy

A 34-year-old male presented with complaints of chest pain and dysphagia for the last 3 months. Endoscopy was normal. HREM done using 24 channel water perfused equipment was suggestive of type 3 achalasia cardia. Patient underwent

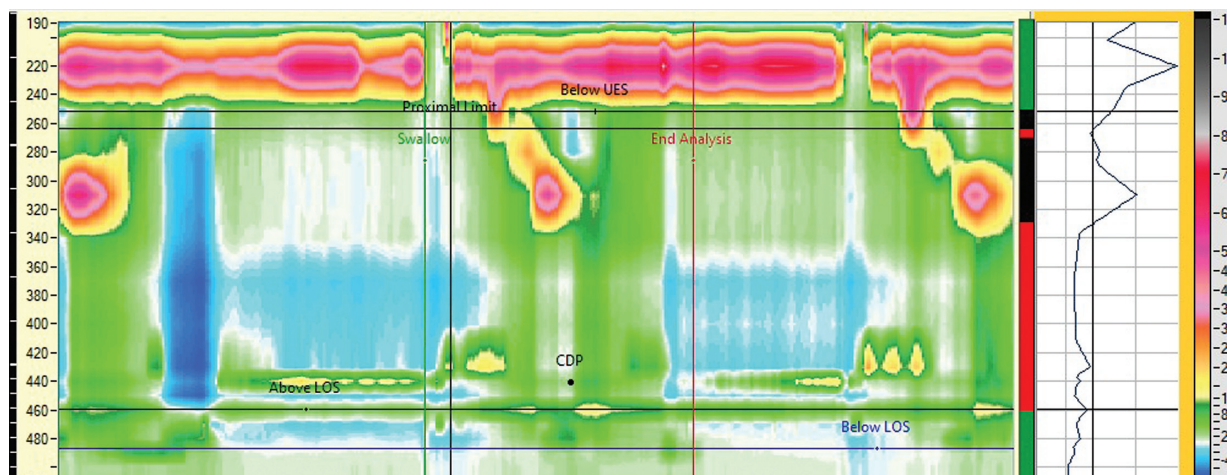


Fig. 4 High-resolution esophageal manometry showing relaxation of remnant muscle using PDE5 inhibitor.

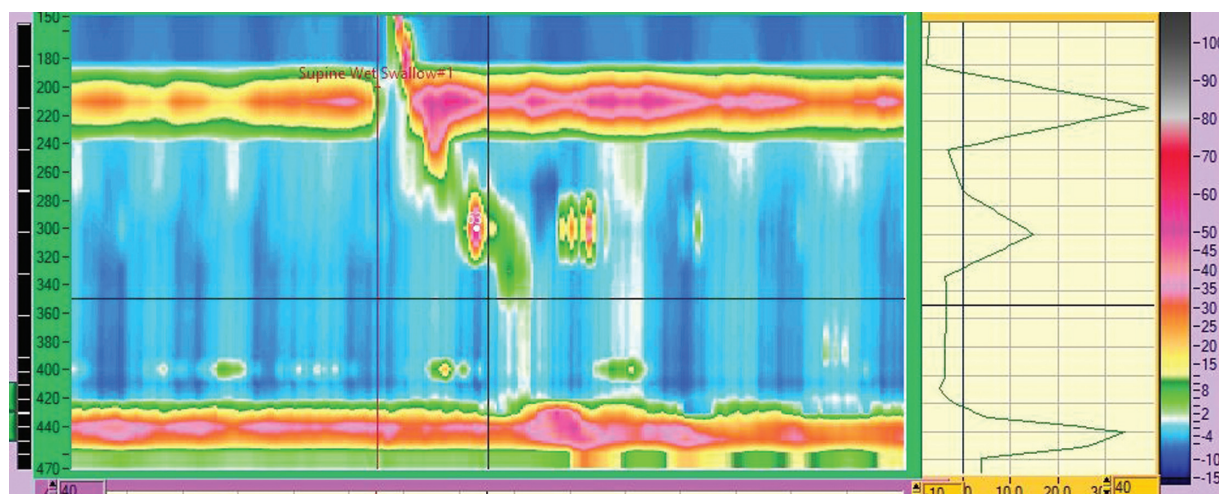


Fig. 5 Raised integrated relaxation pressure after posterior per-oral endoscopic myotomy suggestive of recurrent lower esophageal sphincter dysfunction.

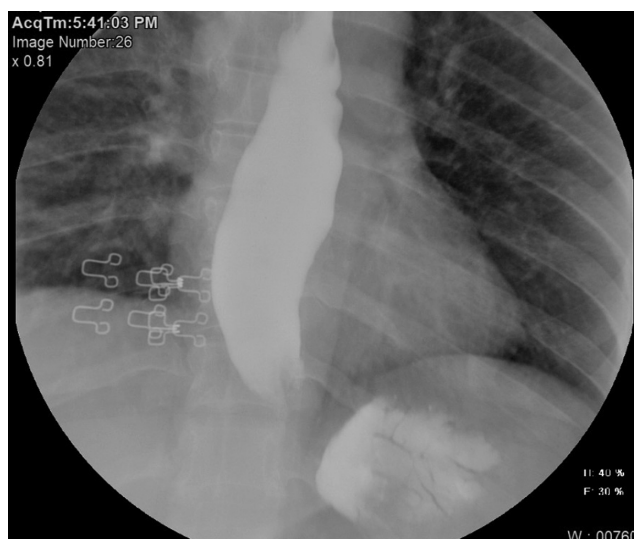


Fig. 6 Retained barium in a patient with suspected POEM failure.

posterior POEM with long myotomy (12 cm) based on HREM findings. Eight months after POEM patient complained of recurrent chest pain while eating. Patient underwent HREM that is showed in ►**Fig. 8**. He also underwent gastrografin study that showed outpouching in the distal esophagus suggestive of blow-out myotomy. ►**Fig. 9** shows the gastrografin study.

Blow-out myotomy is a dreaded complication postmyotomy; this is more common in patients who undergo LHM but it has also been reported after POEM, particularly in patients with type 3 achalasia or patients who undergo long myotomy or redo POEM when there is extensive myotomy. It is particularly difficult to manage this complication. This patient was managed with redo POEM as there was raised IRP as cause of Blown out myotomy (BOM).

In this subset of patients, it is imperative to look at the HREM as this usually happens when there is persistent raised IRP or impaired LES relaxation leading to distal

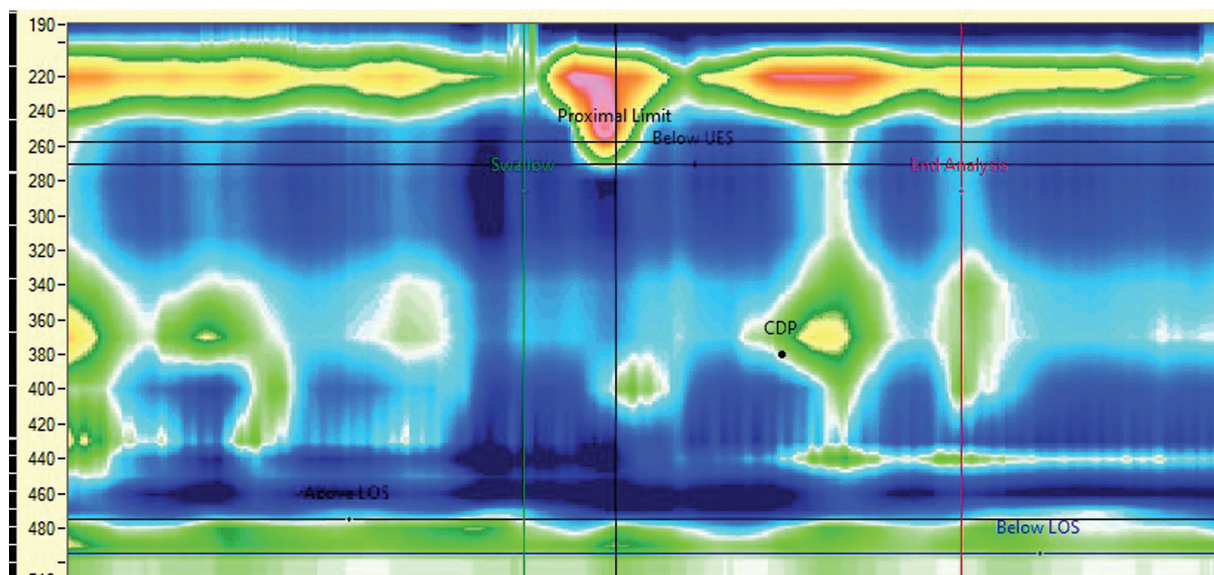


Fig. 7 Absent contractility in the body of esophagus with normal integrated relaxation pressure and normal lower esophageal sphincter pressures.

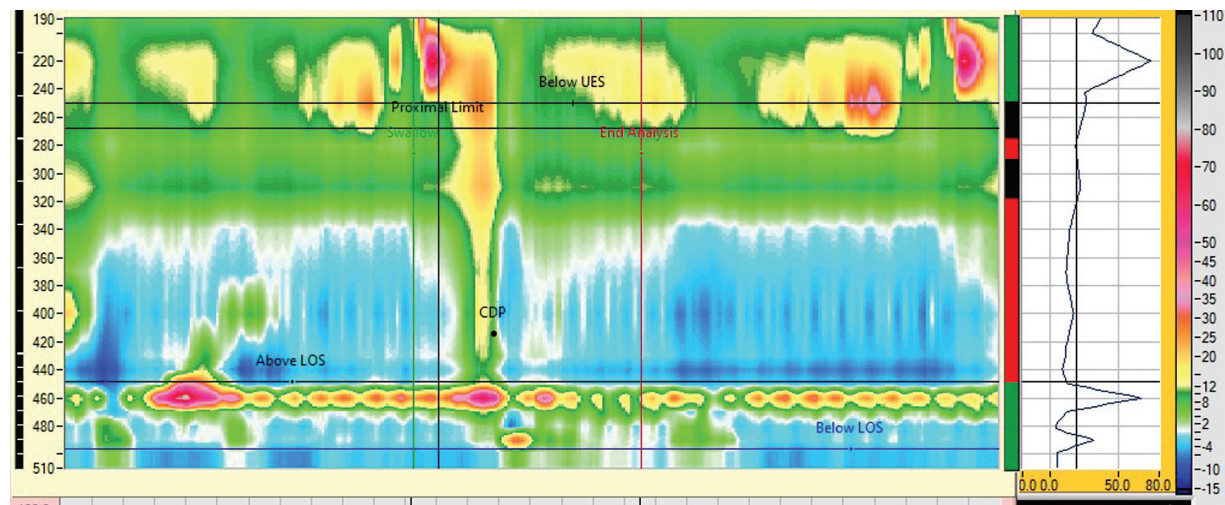


Fig. 8 Post-per-oral endoscopic myotomy with persistent raised integrated relaxation pressure gastrografin of the same patient showed a blow-out myotomy.

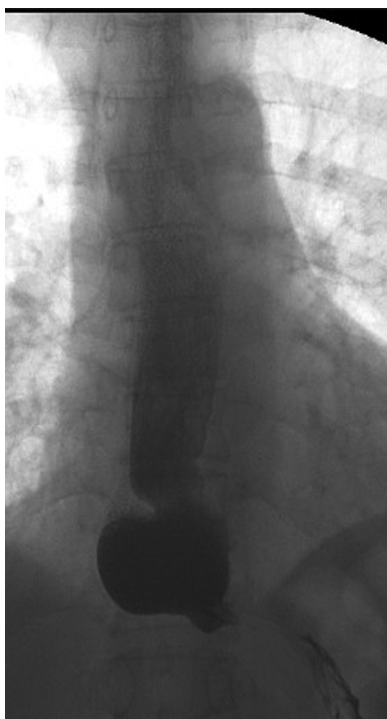


Fig. 9 BOM. Blown out Myotomy post POEM.

pressure zone. Rarely it can happen even without raised LES pressures. Thus, *HREM can decide whether LES-directed therapy or body-directed therapy* can help in these patients or not. If there is impaired LES relaxation, a short LES myotomy may help in relieving the pressures in the blown-out diverticulum.

Case 5: The Case of No POEM Failure

A 66-year-old male was diagnosed as a case of type 1 achalasia cardia and underwent POEM 2 months ago. Initially patient had dysphagia, regurgitation, and nocturnal reflux of

food back. His Eckardt score was 6 pre-POEM with short term relief post-POEM.

He again developed similar symptoms of difficulty in eating and nasal reflux. He underwent esophagogastroduodenoscopy that revealed dilated esophagus with pooling of secretions, but there was no resistance at the level of LES. He then underwent HREM that showed absent contractility consistent with diagnosis of type 1 achalasia cardia and normal IRP at LES that was consistent with no resistance at LES during endoscopy.

In view of nasal regurgitation of symptoms, during same session he underwent high-resolution pharyngeal manometry (HRPM) that showed absence of pharyngeal contractions and low Upper esophageal sphincter (UES) pressures. A local examination by ENT showed vocal cord palsy and uvula deviation while swallowing suggestive of recurrent laryngeal nerve and vagal nerve involvement. **Fig. 10** shows HRPM findings of the patient.

This case reflects a rare occurrence that shows not all recurrence of symptoms is due to POEM failure and one should look out for other causes also.

Conclusion

The above review and case series reflect on use of HREM in assessing symptoms of patients after a failed POEM. It demonstrates use of HREM in identifying the correct therapeutic approach whether LES-directed or esophageal body-directed depending upon the findings on HREM.

Author's Contributions

Z.D.S. conceptualized the article and helped in preparation of manuscript and testing for failures. R.P. conceptualized the article and helped in proof reading of manuscript and final approval.

Conflict of Interest

None declared.

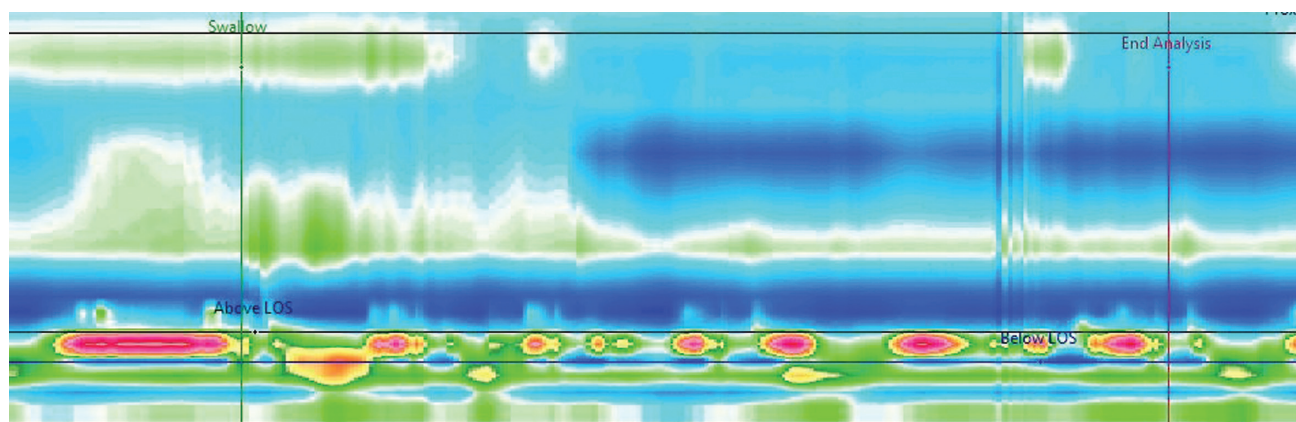


Fig. 10 High-resolution pharyngeal manometry of a patient post-per-oral endoscopic myotomy that showed absent pharyngeal contractility and hypotensive UES.

References

- 1 Inoue H, Minami H, Kobayashi Y, et al. Peroral endoscopic myotomy (POEM) for esophageal achalasia. *Endoscopy* 2010;42(04):265–271
- 2 Nabi Z, Chavan R, Ramchandani M, et al. Long-term outcomes of peroral endoscopic myotomy in spastic esophageal motility disorders: a large, single-center study. *J Clin Gastroenterol* 2021;55(07):594–601
- 3 Werner YB, Hakanson B, Martinek J, et al. Endoscopic or surgical myotomy in patients with idiopathic achalasia. *N Engl J Med* 2019;381(23):2219–2229
- 4 Modayil RJ, Zhang X, Rothberg B, et al. Peroral endoscopic myotomy: 10-year outcomes from a large, single-center U.S. series with high follow-up completion and comprehensive analysis of long-term efficacy, safety, objective GERD, and endoscopic functional luminal assessment. *Gastrointest Endosc* 2021;94(05):930–942
- 5 Ichkhanian Y, Assis D, Familiari P, et al. Management of patients after failed peroral endoscopic myotomy: a multicenter study. *Endoscopy* 2021;53(10):1003–1010
- 6 Vauquelin B, Quéhérvé L, Pioche M, et al. Factors associated with early failure of peroral endoscopic myotomy in achalasia. *Gastrointestinal Endoscopy*, 2023
- 7 Kostic SV, Rice TW, Baker ME, et al. Timed barium esophagogram: a simple physiologic assessment for achalasia. *J Thorac Cardiovasc Surg* 2000;120(05):
- 8 DeWitt JM, Siwiec RM, Perkins A, et al. Evaluation of timed barium esophagogram after per-oral endoscopic myotomy to predict clinical response. *Endosc Int Open* 2021;9(11):E1692–E1701
- 9 Sternbach JM, El Khoury R, Teitelbaum EN. Early esophagram in per-oral endoscopic myotomy (POEM) for achalasia does not predict long-term outcomes. *Surgery* 2015;158(04):1128–1135
- 10 Alonso P, González-Conde B, Macenlle R, Pita S, Vázquez-Iglesias JL. Achalasia: the usefulness of manometry for evaluation of treatment. *Dig Dis Sci* 1999;44(03):536–541